



The Heterogeneous Expressions of Pericardial Disease: A Case Report/Series

Tim Paterick (MD)*

¹Aurora Health Care, United States.

ARTICLE INFO

Article type

Case series

Article history

Received: 19 Mar 2019

Revised: 6 May 2019

Accepted: 10 May 2019

Keywords

Acute Pericarditis

Constriction

Effusive Constrictive Pericarditis

ABSTRACT

Introduction: The pericardium may have various phenotypic manifestations in assorted disease states, such as acute pericarditis, effusive constrictive pericarditis, and constrictive pericarditis. The variety in the phenotypic expressions of pericardial inflammation requires unique clinical and physical examinations and is associated with specific imaging features. The present study aimed to review the normal pericardium and variations of the pericardial disease based on the previously described cases and discuss the clinical manifestations, etiology, diagnostic tools, and treatment methods.

Case Series: A case series of three patients with various phenotypic expressions of pericardial disease have been described. The first patient presented with chest and abdominal pain for three hours. Electrocardiography (ECG) revealed inferior-lateral ST elevation, which was interpreted as an acute coronary syndrome. However, coronary arteriography revealed no obstructive coronary artery disease. Blood tests and ECG post-cardiac catheterization confirmed pericarditis. The second patient had ablation of the cavotricuspid isthmus on the right side of the atrial flutter. After the procedure, the patient had cardiac tamponade and required pericardiocentesis. After two months, the patient presented with tachycardia and hypotension, as well as cardiac tamponade; therefore, pericardiocentesis was performed again. Two years after the second pericardiocentesis, the patient presented with progressive dyspnea. Perfusion imaging revealed anterior wall ischemia, and coronary arteriography revealed three-vessel coronary artery disease. During the bypass surgery, the surgeon was unable to dissect the right and circumflex coronary arteries due to the densely thickened pericardium of the patient. In addition, CT-scan revealed a fibrotic pericardium (thickness: 12 mm). The third patient received chemotherapy and radiation for breast cancer, which resulted in a cancer-free state. However, breast cancer was recurrent, and the patient received treatment with biological Optivo, resulting in cancer remission. After several months, the patient presented with palpitations, dyspnea, and abdominal and leg swelling. Moreover, she had elevated troponin and ECG changes leading to cardiac catheterization with normal coronaries, which were fixed in a dense, thickened serosal pericardium. Subsequent echocardiography revealed evident signs of constrictive pericarditis, and cardiac MRI showed a densely thickened pericardium with diffuse late gadolinium enhancement.

Conclusion: The Phenotypic expressions of pericardial disease are enigmatic and challenging diagnostically. Various forms of pericardial disease may mimic acute coronary syndrome and acute/chronic heart failure. Since each phenotypic presentation of the disease is unique, a rational, linear approach is considered essential to the accurate diagnosis.

Please cite this paper as:

Paterick T. The Heterogeneous Expressions of Pericardial Disease: A Case Report/Series. Rev Clin Med. 2019;6(3):116-122.

***Corresponding author:** Tim Paterick.

Aurora Health Care, United States.

E-mail: tpaterick@gmail.com

Tel: 904-476-4233

This is an Open Access article distributed under the terms of the Creative Commons Attribution License (<http://creativecommons.org/licenses/by/3.0>), which permits unrestricted use, distribution, and reproduction in any medium, provided the original work is properly cited.

Introduction

Pericardium is a unique cardiovascular structure with an innocuous appearance, which is expressed phenotypically in assorted clinical manifestations such as acute pericarditis, effusive-constrictive pericarditis, and constrictive pericarditis. The inflammation of the pericardium may mimic myocardial infarction and prolonged inflammation, thereby leading to constrictive physiology and possibly presenting as heart failure. Variable expressions of pericardial disease cause challenges for the physician.

Normal pericardium consists of visceral and parietal layers, which are separated by a potential space that may contain 15-40 milliliters of serous fluid. The outer parietal layer is fibrous (thickness: <2 mm), and the inner visceral layer is a single layer of cells that are juxtaposed and adherent to the epicardium. Innervated pericardial inflammation could potentially cause chest pain and vagal reflexes (3). The pericardium limits cardiac chamber motions and acute chamber distension. The pericardial space is pressure- and volume-sensitive. Acute fluid accumulation in the pericardial space may lead to hemodynamic compromise, while slow fluid accumulation could be enlarged without hemodynamic effects (5-7).

The present study aimed to review the normal pericardium and variations of the pericardial disease based on the previously described cases and discuss the clinical manifestations, etiology, diagnostic tools, and treatment methods.

Table 1. Baseline Characteristics of Patients

Patient	Age (year)	Gender	ECG		Clinical Presentation	Echocardiography
			Coronary Catheterization	Biomarkers		
1	54	Male		ST Changes Chest Pain	Elevated	Pericardial Inflammation
2	61	Male		ST Changes SOB Three-vessel CAD	Normal	Thick Pericardium
3	39	Female		ST Changes SOB, Edema Normal	Elevated	Thick Pericardium

SOB: shortness of breath; CAD: coronary artery disease

Case Series

Patient One

Presentations on October 8, 2017

The patient presented with acute chest and abdominal pain for three hours. The hemodynamics of the first patients was as follows: blood pressure 100/60 mmHg, hear rate: 110 bpm. The patient

had elevated jugular venous pressure (JVP), distant heart sounds, clear lungs, and no edema. In terms of palpation, normal pulses were observed in the upper and lower extremities. Electrocardiography (ECG) revealed inferior-lateral ST elevation, and the troponin level was elevated as well.

The patient was urgently transferred to the catheterization laboratory, and no coronary artery disease (CAD) was detected. Blood tests revealed the elevated level of C-reactive protein (CRP), and the echocardiogram findings confirmed pericarditis. Treatment was initiated with anti-inflammatory drugs and colchicine.

Presentations on May 12, 2107

Treatment with colchicine and anti-inflammatory drugs resulted in the resolution of the clinical symptoms and ECG changes, and the pericardium had normal pericardial sliding motion on echocardiography without pericardial effusion or pericardial thickening.

Patient Two

Presentations on October 5, 2015

The second patient underwent cavotricuspid isthmus ablation for right-sided atrial flutter. After the procedure, the patient showed the clinical features of cardiac tamponade, manifesting as tachycardia and elevated JVP. In addition, echocardiography revealed a large pericardial effusion with tamponade physiology. Therefore, the patient underwent pericardiocentesis, which resulted in the resolution of tachycardia.

Presentations on December 17, 2015

After two months, the patient experienced tachycardia and shortness of breath. Physical examinations and echo findings indicated recurrent pericardial tamponade, requiring repeated pericardiocentesis, which resulted in the resolution of tachycardia and the associated symptoms.

Presentations on November 6, 2017

The patient returned after two years with the symptoms of progressive shortness of breath. He underwent nuclear stress test, which revealed anterior wall ischemia. Based on this clinical finding, the patient received cardiac catheterization, which provided evidence of three-vessel CAD. Moreover, echocardiography showed preserved left ventricular function. Based on this clinical finding, the patient became a candidate for coronary bypass surgery. The surgeon was able to place a left internal mammary to the left anterior descending coronary artery, while unable to dissect the right and circumflex coronary arteries due to the densely thickened pericardium.

Patient Three

Presentations in January 2010

The third patient was diagnosed with stage 3-A, T3N1Mx left-breast infiltrating ductal carcinoma, which was poorly differentiated, ER-positive, HER2-neutral, and PR-negative. Furthermore, the patient had BRCA-1 syndrome. She received treatment with dose-dense adriamycin, cytoxan chemotherapy, and weekly taxol.

Presentations in March 2011

In 2011, the findings of magnetic resonance imaging (MRI) indicated the marked reduction of the tumor in the left breast. The patient underwent bilateral skin sparing mastectomy, along with left axillary lymph node dissection, which showed 4-16 cancerous nodes. In addition, the patient underwent bilateral salpingo-oophorectomy, and chemotherapy resumed as well.

Presentations in March 2012

The results of positron emission tomography (PET) revealed recurrent disease to the left internal mammary chain. As such, radiation therapy was added to the chemotherapy.

Presentations in January 2013

PET scan showed no evidence of the disease, and chemotherapy and radiation therapy were discontinued.

Presentations in April 2015

The increased tumor markers resulted in more frequent radiation therapy, which resulted in the decline of the tumor markers to the normal range within six months.

Presentations in January 2017

The increased tumor markers necessitated treatment with xeloda, which resulted in the syndrome of inappropriate antidiuretic hormone secretion (SIADH), as well as changes in chemotherapy to Gemzar. Late in 2017, tumor marker elevation steered the treatment to Gemzar cessation, with the introduction of Opdivo at the same time, which altogether led to the remission of the disease.

Presentations in February 2018

The patient referred to the hospital presenting with palpitations, shortness of breath, and abdominal and leg swelling. After admission, elevated troponin was detected. ECG revealed marked ST changes, and echocardiography showed the depressed ejection fraction of 25%. These findings raised concerns regarding an acute coronary syndrome, prompting immediate cardiac cath-

eterization. However, catheterization revealed no obstructive CAD. Epicardial coronary arteries were entrapped in the thickened serosal pericardium, which is the characteristic of chronic constrictive pericarditis.

Case Presentation

Patient One

A 54-year-old male patient referred to the emergency section, presenting with chest and abdominal pain for three hours. The blood pressure of the patient was 100/60 mmHg, and the pulse rate was 110 bpm. The heart sounds of the patient were muffled, while the lungs were clear, and no peripheral edema was detected. In addition, the pulse was full in the upper and lower extremities.

ECG revealed inferior-lateral ST elevation, which was interpreted as acute myocardial infarction (Figure 1). The patient was urgently transferred to the cardiac catheterization laboratory, and obstructive CAD was not diagnosed (Figures 2 & 3).

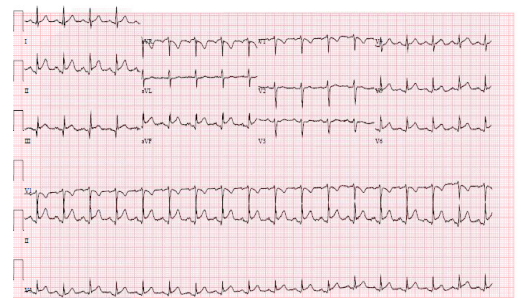


Figure 1. Sinus Tachycardia and Inferior and Lateral ST Elevation without Reciprocal Changes.

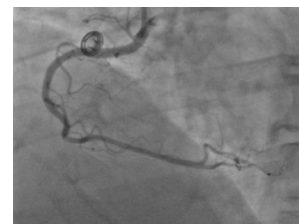

Figure 2. RCA Free of Obstructive Disease.

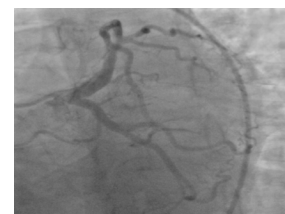


Figure 3. Circumflex and LAD Free of Obstructive Disease.

On the other hand, blood test and post-cardiac catheterization echocardiogram confirmed the diagnosis of pericarditis. Elevations were observed in troponin, CRP, and sedimentation rate. Moreover, the echocardiograms demonstrated an

inflammatory manifestation in the form of small pericardial effusion and thickened pericardium, while no echo features of constriction were observed (Figure 4) (Cine 1,2).

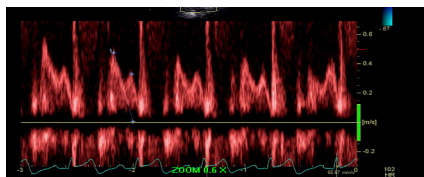


Figure 4. Mitral Inflow without Respiratory Variation.

Treatment with colchicine and anti-inflammatory drugs resulted in the resolution of the ECG changes and clinical symptoms (Figure 5). In addition, echocardiography revealed normal left ventricular function with normal pericardium without pericardial effusion. Therefore, no additional imaging was performed.

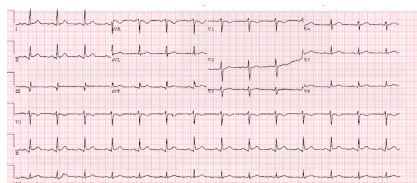


Figure 5. Post-treatment ECG Revealing Resolution of ST Segment Changes.

Patient Two

A 61-year-old male with paroxysmal atrial fibrillation underwent an electrophysiology evaluation. There was coronary sinus lead placement for the recording and pacing of the left atrial electrogram, as well as the ablation of the cavotricuspid isthmus in the right atrial flutter. After the procedure, the patient had sinus rhythm, tachycardia, hypotension, and shortness of breath. Examinations revealed a large pericardial effusion, which led to the tamponade hemodynamics requiring percutaneous pericardiocentesis. At this stage, 300 millimeters of the straw-colored fluid was removed, which resulted in the restoration of normal hemodynamics and alleviation of the shortness of breath. After two months, the patient experienced tachycardia and shortness of breath again. Echocardiography revealed a large pericardial effusion with echocardiographic features, suggesting cardiac tamponade. Therefore, the patient underwent pericardiocentesis with the resolution of the symptoms.

After two years, the patient referred again, presenting with the symptoms of progressive shortness of breath (blood pressure: 140/90 mmHg, pulse rate: 76 bpm). The patient had normal heart sounds, and the lungs were clear with no peripheral edema. In addition, the pulse was full in the

upper and lower extremities.

The nuclear stress test revealed anterior wall ischemia, and the patient received cardiac catheterization. Catheterization showed evidence of three-vessel CAD (Figures 6-8), and the echocardiography revealed preserved left ventricular function. Based on this clinical finding, the patient was prescribed to undergo coronary bypass surgery. The surgeon was able to place a left internal mammary to the left anterior descending coronary artery, while unable to dissect the right and circumflex coronary arteries due to the densely thickened pericardium.

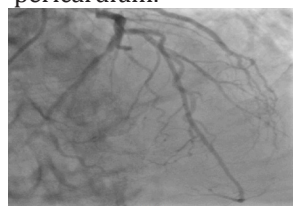


Figure 6. Moderate LAD Disease

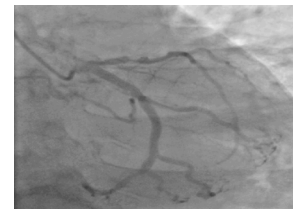


Figure 7. Mild Circumflex Disease

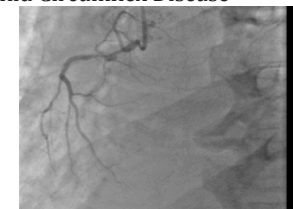

Figure 8. Small, Nondominant RCA

The patient was received treatment with anti-inflammatory medications, including nonsteroidal anti-inflammatory drugs and colchicine for six months. Nevertheless, the echo features of pericardial constriction persisted. The patient continued to have exertional shortness of breath despite the declined pericardial stripping. Cardiac CT scan revealed a densely thick and fibrotic pericardium, which led to dissection so as to determine the missing findings in the evaluation of the patient who presented with exertional dyspnea. Echocardiogram and catheterization were reviewed, and no imaging modalities had clues for pericardial constriction. The inferior vena cava (IVC) was dilated without respiratory variation (Figure 9), and the Doppler data revealed interventricular interdependence with inspiratory decline in the stroke volume and mitral E wave (Figures 10 & 11), as well as a prominent septal bounce (Cine 3). Furthermore, the normal sliding motion of the pericardium was not observed (Cine 4).

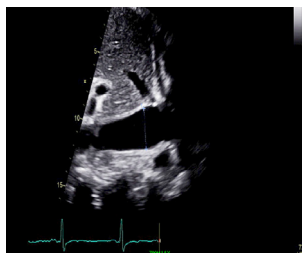


Figure 9. Dilated IVC

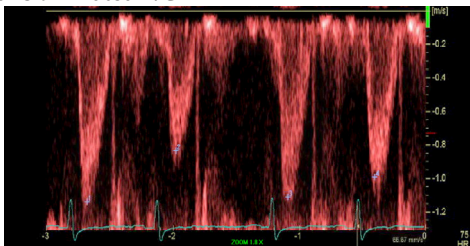


Figure 10. Respiratory Variations in Stroke Volume

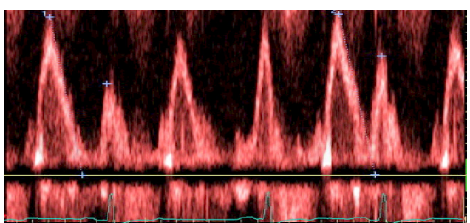


Figure 11. Respiratory Variations in E Wave

Tissue Doppler showed annulus reversus. Additionally, the review of the cardiac catheterization revealed the loss of the normal motion of the coronary vessels distally (Cine 5), which is a classic feature of effusive constrictive pericarditis evolving into constrictive pericarditis. The initial ablation studies caused an inflammatory process and recurrent pericardial effusions in the patient. Meanwhile, the persistence of the elevated right atrial and ventricular pressure was not recognized. The shortness of breath in the patient was probably multifactorial, while constriction was undoubtedly involved in dyspnea. This highlights the subtlety and complexity of identifying pericardial constriction. In this case, the diagnostic clues were the clinical history and careful scrutiny of the catheterization and echo features.

Patient Three

A 39-year-old female patient referred to the hospital presenting with palpitation, shortness of breath, and increasing abdominal bloating and leg swelling. The examinations revealed the blood pressure of 90/60 mmHg and heart rate of 110 bpm. In addition, she had elevated JVP, ascites, and lower-extremity edema. The patient was also observed to have elevated troponin. ECG showed absent R waves, V 1-3, and ST elevation, while an urgent echocardiogram revealed reduced left

ventricular systolic function with (left ventricular ejection fraction=25%). This constellation of symptoms, physical examination findings, and laboratory results led to an urgent heart catheterization, revealing normal coronary arteries. On the other hand, the epicardial coronary arteries were entrapped in a thickened serosal pericardium, which is a feature of constrictive pericarditis.

The repeated comprehensive echocardiogram revealed a plethoric IVC, and the Doppler data showed interventricular interdependence, septal bounce, blunted superior vena cava flow, and low pericardial sliding motion, all of which confirmed the diagnosis of constrictive pericarditis. The patient was referred to a center of excellence for pericardial stripping. Postoperatively, she returned to class 1 functional capacity with no symptoms.

Discussion

Acute Pericarditis

Acute pericarditis may occur as an acute localized inflammatory response in the pericardial space or an autoimmune response to an underlying systemic disease (6). Acute pericardial inflammation may occur with or without pericardial effusion. Approximately 90% of localized, acute pericarditis is viral or idiopathic. Several systemic diseases may precipitate acute pericardial inflammation, including uremia, connective tissue disorders, vasculitis, malignancy, post-transmural myocardial infarction, and postpericardiotomy (7-9). Patients with post-transmural myocardial infarction may develop pericarditis within 1-3 days after the infarction. Dressler's syndrome is an autoimmune reaction, which attacks the pericardial space within weeks to months after infarction, mimicking pericarditis. It is notable that the rate of post-infarction pericarditis has reduced since the introduction of reperfusion therapy (11).

Clinical Manifestations of Acute Pericarditis

Pericarditis may present with or without symptoms although the patients typically have chest pain, which amplifies with deep breathing and positional changes. The etiology of the chest pain is phrenic nerve irritation. The differential diagnosis of pericarditis should include myocardial ischemia/infarction, pulmonary embolism, and pleurisy.

Auscultation may reveal a pericardial friction rub that is scratchy and may have 1-3 separate components. The distinction between pleurisy and pericarditis is established by having the patient stop breathing, and the persistence of the rub confirms pericardial irritation.

It is noteworthy that the absence of pericardial

effusion does not rule out pericarditis. Cardiac CT-scan could identify the inflamed pericardium in the absence of effusion on echocardiography (12).

The ECG features of acute pericarditis follow a temporal pattern:

- Stage 1: diffuse ST-segment elevation and PR depression with ST depression and PR elevation in aVR;
- Stage 2: normalization of the ST and PR segments;
- Stage 3: widespread T-wave inversions;
- Stage 4: normalization of T waves

The laboratory findings associated with acute pericarditis reflect the inflammatory process with leukocytosis, elevated inflammatory biomarkers, and elevated troponin. Troponin elevation may persist for 1-2 weeks (13-15).

Treatment

In general, acute pericarditis responds to high-dose aspirin (ASA) therapy or non-steroidal anti-inflammatory drugs (NSAIDs) without residual, long-term side-effects. ASA is preferred over NSAIDs in case of post-myocardial infarction since NSAIDs may impair myocardial healing (5). Concurrent use of colchicine is recommended based on the results of the Colchicine for Acute Pericarditis (COPE) Trial (16). However, steroids are not recommended due to the initial positive response if it is frequently followed by the relapse of pericardial inflammation, with the exception of the steroids that may be necessary when patients do not respond to NSAIDs and colchicine. This issue could be handled optimally by a specialist in pericardial disease.

Effusive Constrictive Pericarditis

In a small number of patients, cardiac tamponade evolves into pericardial constriction. A signature clue in this regard is that the elevation of the right atrial pressure persists after pericardiocentesis (17). A series of cases with effusive-constrictive pericarditis has been reported, including 218 patients with cardiac tamponade. All these cases underwent pericardiocentesis, and 15 cases had constrictive pericarditis in the follow-up. The common etiologies were reported to be radiation, malignancy, and idiopathic pericarditis. Among these patients, 12 cases required pericardiectomy (18). Heart failure persisted in patient two despite optimal medical therapy, and the patient refused cardiac surgery consultation for pericardial stripping.

Pericardial Constriction

The pathophysiology of pericardial constriction is the equalization of the end-diastolic pressure in all the cardiac chambers. Thick, fixed, and often

calcified pericardium impairs cardiac filling with diminished stroke volume in the presence of reflexive tachycardia. On the other hand, non-compliant pericardium conceals the cardiac chambers from respiratory alterations in intrathoracic pressure, thereby leading to the paradoxical rise in JVP, along with inspiration. This is considered to be a well-known Kussmaul sign.

Etiology

Pericardial constriction occurs after the persistence of an inflamed pericardium that thickens, fibroses, and calcifies. The common etiologies include mediastinal radiation, cardiac surgery, and relapsing pericarditis (21).

Clinical Manifestations

Patients typically present with elevated JVP, hepatic congestion with ascites, and lower-extremity edema. Furthermore, they have low cardiac output, as well as exercise intolerance and right-sided heart failure. Expert clinicians auscultate a pericardial knock, which is a high-pitched sound in the early diastole due to the sudden cessation of diastolic filling (22).

Most of the patients with pericardial constriction show the pericardium thickness of more than two millimeters in CT-scan or MRI. The Mayo Clinic has reviewed the surgical specimens of these patients after pericardiectomy, reporting that approximately 20% of these patients have normal pericardial thickness (23).

- Acute pericarditis may mimic acute coronary syndrome, and echocardiographic imaging may allow clinicians to distinguish myocardial infarction from an acute inflammatory pericardial state.
- Effusive-constrictive pericarditis may manifest as cardiac tamponade and/or acute heart failure. The most common causes of effusive-constrictive pericarditis are idiopathic conditions, malignancies, and radiation. It is often a transition phase between acute pericarditis and pericardial constriction.
- The distinguished feature of pericardial constriction is thickened, fibrotic, and frequently calcified pericardium, which impairs cardiac filling, ultimately leading to diminished cardiac output. The hemodynamic effect of pericardial restriction is the equalization of the end-diastolic pressure in all the cardiac chambers, which occurs due to the fact that limited pericardial volume determines the filling pressure. Constriction often presents as right-sided heart failure.

Conclusion

The three cases presented in this case series demonstrate the spectrum of pericardial disease.

Acute pericarditis is typically self-limited and may mimic acute coronary syndrome. Cardiac tamponade may be life-threatening and requires prompt diagnosis and pericardiocentesis in case of hemodynamic compromise. It is important to note that effusive-constrictive pericarditis could transform into pericardial constriction. Pericardial constrictive typically manifests as right-sided heart failure. The spectrum of pericardial disease is heterogeneous and variable and may mimic other disease processes. Therefore, the accurate diagnosis of pericardial disease requires the awareness of its various presentations, perceptive physical examination skills, and detailed cardiac imaging.

Acknowledgements

None.

Conflict of Interest

The authors declare no conflict of interest.

References

- Maisch B, Seferovic PM, Ristic AD, et al. Guidelines on the diagnosis and management of pericardial diseases: executive summary. *Eur Heart J*. 2004; 25: 587–610.
- Spodick DH. Macrophysiology, microphysiology, and anatomy of the pericardium: a synopsis. *Am Heart J*. 1992; 124:124: 1046–1051.
- Miyazaki T, Pride HP, Zipes DP. Prostaglandins in the pericardial fluid modulate neural regulation of cardiac electrophysiological properties. *Circulation Res*. 1990; 66: 163–175.
- Applegate RJ, Johnston WE, Vinten-Johansen J, et al. Restraining effect of intact pericardium during acute volume loading. *Am J Physiol*. 1992; 262: H1725–H1733.
- Lange RA, Hillis D. Acute pericarditis. *N Engl J Med*. 2004; 351:2195–2202.
- Fowler NO. Tuberculous pericarditis. *JAMA*. 1991. 266: 99–103.
- Gunukula SR, Spodick DH. Pericardial disease in renal patients. *Semin Nephrol*. 2001;21:52-56.
- Mandell BF. Cardiovascular involvement in systemic lupus erythematosus. *Semin Arthritis Rheumatol*. 1987; 17: 5256.
- Figueras J, Juncal A, Carballo J, et al. Nature and progression of pericardial effusion in patients with a first myocardial infarction: relationship to age and free wall rupture. *Am Heart J*. 2002; 144: 251–258.
- Jerjes-Sanchez C, Ramirez – Rivera A, Ibbara-Perez C. The Dressler syndrome after pulmonary embolism. *Am J Cardiol*. 1996; 78: 342-345.
- Correale E, Maggioni AP, Romano S, et al. Pericardial involvement in acute myocardial infarction in the post-thrombolytic era: clinical meaning and value. *Clin Cardiol*. 1997;20:327–331.
- Spodick DH. Acute pericarditis: current concepts and practice. *JAMA*. 2003; 289: 1150-1153.
- Imazio M, Gaita F. Diagnosis and treatment of pericarditis. *Heart*. 2015; 101: 1159-1168.
- Bonnefoy E, Godon P, Kirkorian G, et al. Serum cardiac troponin 1 and ST segment elevation in patients with acute pericarditis. *Eur Heart J*. 2000; 21: 832-836.
- Imazio M, Demichellis B, Cecchi E, et al. Cardiac troponin 1 in acute pericarditis. *J Am Coll Cardiol*. 2003; 42: 2144-2148.
- Imazio M, Bobbio M, Cecchi E, et al. Colchicine in addition to conventional therapy for acute pericarditis: results of the COLchicine for acute PERicarditis (COPE) trial. *Circulation*. 2005;112:2012-2016.
- Hancock EW. Sub-acute effusive-constrictive pericarditis. *Circulation*. 1971;43: 183-192.
- Sagrìstà-Sauleda J, Angel J, Sánchez A, et al. Effusive-constrictive pericarditis. *N Engl J Med*. 2004; 350: 469-475.
- Haley JH, Tajik J, Danielson GK, et al. Transient constrictive pericarditis: causes and natural history. *J Am Coll Cardiol*. 2004; 43: 271-275.
- Shebetal R, Fowler NO, Guntheroth WG. The hemodynamics of cardiac tamponed and constrictive pericarditis. *Am J Cardiol*. 1970; 26: 480-489.
- Ling LH, Oh JK, Breen JF, et al. Calcified constrictive pericarditis: Is it still with us? *Ann Intern Med*. 2000; 132: 444-450.
- Tyberg TI, Goodyer AV, Langou RA. Genesis of pericardial knock in constrictive pericarditis. *Am J Cardiol*. 1980; 46: 570-575.
- Talreja DR, Edwards WD, Danielson GK, et al. Constrictive pericarditis in 26 patients with histologically normal pericardial thickness. *Circulation*. 2003;108:1852-1857.