



Central venous line complications and tip detection

Ameneh Rezaee Gheshlaghi (MD)¹, Hamid Zamani Moghadam Dolu (MD)^{1*}, Elham Pishbin (MD)¹,
Maryam Salehi (MD)²

¹ Department of Emergency Medicine, School of Medicine, Mashhad University of Medical Sciences, Mashhad, Iran.

² Department of Community Medicine, School of Medicine, Mashhad University of Medical Sciences, Mashhad, Iran.

ARTICLE INFO

Article type

Review article

Article history

Received: 14 Apr 2014

Revised: 26 Apr 2014

Accepted: 30 Apr 2014

Keywords

Central venous line

Emergency department

Rapid fluid therapy

Tip misplace

ABSTRACT

Central venous line is one of a creative instrument that saves human's life in critical medical situation. Central venous line access is frequently involved in the disease management. It is used for rapid fluid therapy, transvenous pacemakers, infusion of some medications, hemodialysis or plasmapheresis and etc. Most of the emergency departments have some staffs that are trained for central venous line insertion but related complications occur during central venous line placement.

Central venous line might have some complications and complication follow-up should be considered. Thromboembolism and infection are two important medical complications. Arterial puncture, hematoma, pneumothorax and hemothorax are mechanical Central venous line complications. Chest X-ray and some other techniques should be used for detecting these complications.

Central venous line tip misplace is a considerable problem for emergency department staffs, previously chest X-ray has been used for central venous line misplace detection. In some recent studies, contrast-enhanced ultrasonography and intravascular electrocardiography have been used for central venous line misplace.

Please cite this paper as:

Gheshlaghi AR, Zamani Moghadam Dolu H, Pishbin E, Salehi M. Central venous line complications and tip detection. *Rev Clin Med*. 2015;2(3):158-160.

Introduction

Central venous line (CVL) access is frequently involved in the disease management such as surgical-oncological patients, parenteral nutrition and etc. (1,2).

Advanced hemodynamic monitoring, rapid fluid therapy, transvenous pacemakers and infusion of some medications, all require consistent CVL (3). In the United State, more than 5 million CVL were performed in a year (4). The first CVL access was placed in 1667 and a sheep was transfused blood from carotid artery (3). Nobel Prize was given to the pioneer of CVL in 1956 to Werner Forssmann for his first modern CVL access (3,5).

However, venous access might be a problem

in some cases such as infants, ill children or shocked patients (6).

Central venous pressure (CVP) and oximetry monitoring are other usages of CVL (3). Some CVL indications are high-volume/flow resuscitation, emergency venous access, repetitive blood sampling, administering hyperalimentation, caustic agents, insertion of cardiac pacemakers, hemodialysis or plasmapheresis and insertion of pulmonary artery catheters (3).

Major complication and CVL site

CVL is one of the most important risk factor for thromboembolism in patients (7). Another

***Corresponding author:** Hamid Zamani Moghadam.

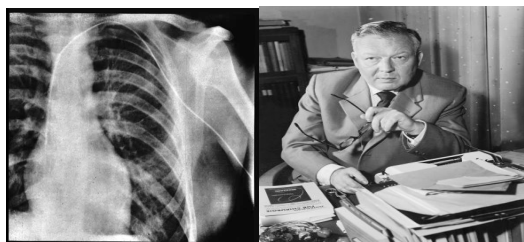
Department of Emergency Medicine, School of Medicine, Mashhad University of Medical Sciences, Mashhad, Iran.

E-mail: Zamanimh@mums.ac.ir

Tel: 05138525312

This is an Open Access article distributed under the terms of the Creative Commons Attribution License (<http://creativecommons.org/licenses/by/3.0>), which permits unrestricted use, distribution, and reproduction in any medium, provided the original work is properly cited.

Figure 1. Werner Forssmann (1979-1904), his first X-ray when used CVL



major complication is infection (8). Some studies showed that the morbidity and mortality of CVL were due to its serious complications (9,10). Some of these complications are listed below:

1. Arterial puncture
2. Hematoma
3. Pneumothorax
4. Hemothorax
5. Air embolism
6. Infection
7. Thrombosis
8. Nerve injury
9. Arrhythmia due to CVL
10. Tip misplacement (3)

According to the Bozzetti F et al. CVL complications took place in about 25% of patients (11). However, in another study, the prevalence of CVL complications were mentioned in about 15% of patients. Some of these complications related to the place of CVL were reported as infection due to femoral CVL and pneumothorax due to jugular CVL (4). Minimal risk of infection has been ob-

served for subclavian CVL access (12).

Most of these complications are preventable or treatable but emergency department staffs (EDS) should consider them.

For example, for following up the thorax complications, an upright or semi-upright chest X-ray should be performed as soon as possible (3,10,12).

One of the rare complications is superior vena cava injury due to CVL (13).

Site of venous approach could be one of malposition of CVL (14). The most important result of Sibylle Ruesch meta-analysis shows that there are more arterial punctures but less catheter malpositions with the internal jugular compared with the subclavian access (15).

However, some authors believed that no powerful evidence has shown that CVL should be placed in internal jugular or subclavian (16).

According to the Table 1, EDS should choose the best places of CVL in patients.

Central venous line misplaced detection

CXR is a reference standard for correct placement of CVL (3,12). In addition, intravascular electrocardiography (ECG) has been used for detecting the true place of CVL just before Sinoatrial (SA) node in right atrium (17).

P-wave amplitude could be a great index of appropriate place of CVL. The highest P wave find in the optimal location (18). Gebauer et al. used ultrasound-guided method for reaching optimal location of CVL (19).

Contrast-enhanced ultrasonography could be

Table1. Advantage and disadvantage of the CVL place.

Place (Reference)	Advantage	Disadvantage
Internal Jugular (3)	Good external landmarks Improved success with ultrasound Less risk for pneumothorax than subclavian access Can recognize and control bleeding Malposition of the catheter is rare Almost a straight course to the superior vena cava on the right side Carotid artery easily identified	More difficult and inconvenient to secure Possibly higher infectious risk than subclavian access Possibly higher risk for thrombosis than subclavian access
Femoral (10)	Good external landmarks Useful alternative with coagulopathy	Difficult to secure in ambulatory patients Not reliable for CVP measurement Highest risk for infection Higher risk for thrombus
Subclavian (12)	Good external landmarks	Unable to compress bleeding vessels "Blind" procedure Should not be attempted in very young children or less than 2 years old

another technique for detecting the appropriate place of CVL in EDs (20). It is very fast, available and acceptable as screening test. However, CXR as gold standard could detect the CVL complications such as pneumothorax and hemothorax.

Contrast-enhanced ultrasonography had negative predictive value of 94% (95% CI, 89%-100%) in Cortellaro and his research team study versus the CXR (20).

Conclusion

Central venous line is one of a creative instrument that saves human's life in critical medical situation. It has been used for many medical conditions.

However, it might have some complications and complication follow-up should be considered by CXR and some other techniques.

In some recent studies, contrast-enhanced ultrasonography and some older techniques such as intravascular ECG have been used for CVL misplace detection. By the way, tip detection of CVL is a very important step.

Acknowledgement

We would like to thank Clinical Research Development Center of Ghaem Hospital for their assistant in this manuscript. This study was supported by a grant from the Vice Chancellor for Research of the Mashhad University of Medical Sciences for the research project as a medical student thesis with approval number of 920420.

Conflict of Interest

The authors declare no conflict of interest.

References

1. Male C, Chait P, Andrew M, et al. Central venous line-related thrombosis in children: association with central venous line location and insertion technique. *Blood*. 2003;101:4273-4278.
2. Marano L, Izzo G, Esposito G, et al. Peripherally inserted central catheter tip position: a novel empirical-ultrasonographic index in a modern surgical oncology department. *Ann Surg Oncol*. 2014;21:656-661.
3. Roberts JR, Custalow CB, Thomsen TW, et al. *Clinical Procedures in Emergency Medicine*. 6 ed: Elsevier - Health Sciences Division; 2013.
4. McGee DC, Gould MK. Preventing complications of central venous catheterization. *N Engl J Med*. 2003;348:1123-1133.
5. Goerig M, Agarwal K. [Werner Forssmann: "the typical man before his time!" - self-experiment shows feasibility of cardiac catheterization]. *Anesthesiol Intensivmed Notfallmed Schmerzther*. 2008;43:162-165.
6. Saleem MM. Cost-effective central venous line for infants in the developing world. *Singapore Med J*. 2009;50:522-524.
7. Halton J, Nagel K, Brandao LR, et al. Do children with central venous line (CVL) dysfunction have increased risk of symptomatic thromboembolism compared to those without CVL-dysfunction, while on cancer therapy? *BMC Cancer*. 2012;12:314.
8. Decker MD, Edwards KM. Central venous catheter infections. *Pediatr Clin North Am*. 1988;35:579-612.
9. Tweddle DA, Windebank KP, Barrett AM, et al. Central venous catheter use in UKCCSG oncology centres. United Kingdom Children's Cancer Study Group and the Paediatric Oncology Nursing Forum. *Arch Dis Child*. 1997;77:58-59.
10. Frykholm P, Pikwer A, Hammarskjold F, et al. Clinical guidelines on central venous catheterisation. *Acta Anaesthesiol Scand*. 2014;58:508-524.
11. Bozzetti F, Mariani L, Bertinet DB, et al. Central venous catheter complications in 447 patients on home parenteral nutrition: an analysis of over 100,000 catheter days. *Clin Nutr*. 2002;21:475-485.
12. McKinley S, Mackenzie A, Finfer S, et al. Incidence and predictors of central venous catheter related infection in intensive care patients. *Anaesth Intensive Care*. 1999;27:164-169.
13. Bagheri R, Nurshafiee S. Superior vena cava injury after central venous catheterization: a case report. *Tehran University Medical Journal*. 2010;68.
14. Maffessanti M, Bortolotto P, Kette F. [Malpositions and complications following central venous catheterization in relation to the access site]. *Radiol Med*. 1988;75:609-612.
15. Ruesch S, Walder B, Tramer MR. Complications of central venous catheters: internal jugular versus subclavian access--a systematic review. *Crit Care Med*. 2002;30:454-460.
16. Ameh V, Jones S. Best evidence topic report. Central venous catheterisation: internal jugular or subclavian approach? *Emerg Med J*. 2007;24:662-663.
17. Artru AA, Colley PS. The site of origin of the intravascular electrocardiogram recorded from multiorificed intravascular catheters. *Anesthesiology*. 1988;69:44-48.
18. Smith B, Neuharth RM, Hendrix MA, et al. Intravenous electrocardiographic guidance for placement of peripherally inserted central catheters. *J Electrocardiol*. 2010;43:274-278.
19. Gebauer B, Teichgraber UK, Podrabsky P, et al. [Ultrasound- and fluoroscopy-guided implantation of peripherally inserted central venous catheters (PICCs)]. *Rofo*. 2004;176:386-391.
20. Cortellaro F, Mellace L, Paglia S, et al. Contrast enhanced ultrasound vs chest x-ray to determine correct central venous catheter position. *Am J Emerg Med*. 2014;32:78-81