



Peritonitis Due to *Rothia dentocariosa* in Iran: A Case Report

Kobra Salimiyan Rizi (Ph.D Candidate)¹, Hadi Farsiani (Ph.D)*², Kiarash Ghazvini (MD)²,
Masoud Youssefi (Ph.D)²

¹Department of Microbiology and Virology, School of Medicine, Mashhad University of Medical Sciences, Mashhad, Iran.

²Antimicrobial Resistance Research Center, Mashhad University of Medical Sciences, Mashhad, Iran.

ARTICLE INFO

Article type

Case report

Article history

Received: 19 Feb 2019

Revised: 19 Mar 2019

Accepted: 22 Mar 2019

Keywords

Oral Hygiene

Peritoneal Dialysis

Rothia dentocariosa

ABSTRACT

Rothia dentocariosa (*R. dentocariosa*) is a gram-positive bacterium, which is a microorganism that normally resides in the mouth and respiratory tract. *R. dentocariosa* is known to involve in dental plaques and periodontal diseases. However, it is considered an organism with low pathogenicity and is associated with opportunistic infections. Originally thought not to be pathogenic in humans, *R. dentocariosa* was first described to cause infections in a 19-year-old female with periappendiceal abscess in 1975. The most prevalent human infections caused by *R. dentocariosa* include infective endocarditis, bacteremia, endophthalmitis, corneal ulcer, septic arthritis, pneumonia, and peritonitis associated with continuous ambulatory peritoneal dialysis. Three main factors have been reported to increase the risk of the cardiac and extra-cardiac infections caused by *R. dentocariosa*, including immunocompromised conditions, pre-existing cardiac disorders, and poor oral hygiene. Peritoneal dialysis (PD) may induce peritonitis presumably due to hematogenous spread from gingival or periodontal sources. This case study aimed to describe a former PD patient presenting with peritonitis. Oral hygiene is a basic principle in PD patients for the prevention of peritonitis. It is speculated that our patient might have had an occult oral source of *R. dentocariosa*.

Please cite this paper as:

Salimiyan Rizi K, Farsiani H, Ghazvini K, Youssefi M. Peritonitis Due to *Rothia dentocariosa* in Iran: A Case Report. Rev Clin Med. 2019;6(1):37-39.

Introduction

Rothia is a pleomorphic, gram-positive bacterium, which is coccoid, rod-shaped or filamentous, with the potential branching belonging to the family Micrococcaceae. In general, it is considered to be a harmless oropharynx commensal (1,2). *Rothia* is a genus of the bacteria that are filamentous, non-spore-forming, non-motile, and facultatively anaerobic, which is associated with fermentative metabolism and variable in terms of oxidase-negative and catalase. The most important pathogenic species in this genus include *R. terrae*, *R. mucilaginosus*, *R. amarae*, *R. aerea*, *R. nasimurium*, and *R.*

dentocariosa (3). *R. dentocariosa* is the type species of this genus.

R. dentocariosa is a catalase-positive acid producer from ribose, fructose, glucose, maltose, salicin, sucrose, trehalose, and Voges-Proskauer positive reaction (3). It is found in more than 30% of healthy humans (4) and is known to be involved in dental plaques and periodontal diseases (5). However, it is considered an organism with low pathogenicity and is associated with opportunistic infections (6). Some of the most common human infections caused by *R. dentocariosa* include

*Corresponding author: Hadi Farsiani.

Antimicrobial Resistance Research Center, Mashhad University of Medical Sciences, Mashhad, Iran.

E-mail: farsianih@mums.ac.ir

Tel: +989127853225

This is an Open Access article distributed under the terms of the Creative Commons Attribution License (<http://creativecommons.org/licenses/by/3.0>), which permits unrestricted use, distribution, and reproduction in any medium, provided the original work is properly cited.

infective endocarditis, bacteremia, endophthalmitis, corneal ulcer, septic arthritis, pneumonia, and peritonitis associated with continuous ambulatory peritoneal dialysis (PD) (7). In fact, *R. dentocariosa* rarely appears as an unanticipated pathogen in the earnest infections of the human body, most notably in infective endocarditis, endophthalmitis, peritonitis in PD patients, and bacteremia.

This case study aimed to describe a former PD patient presenting with peritonitis.

Case report

A 40-year-old female presented with end-stage renal disease (ESRD) for the past 31 years due to chronic hypertension. In December 5, 2018, the patient was admitted to Imam Reza Hospital in Mashhad, Iran for pain assessment in the entire body, particularly abdominal pain, fever, nausea, fatigue, purulent, abdominal tenderness, and cloudy PD fluid.

The patient was pyrexic with the temperature of 38.7°C and hypertensive (153/110 mmHg), and

the respiratory rate was 21 breaths per minute. Furthermore, the dialysate fluid leukocyte count of the patient was 1,550 per microliter, and her peripheral leukocyte count was $17.8 \times 10^9/l$ with neutrophilic dominance. Two bottles of blood culture were collected from the patient and cultured by the automated method of BACTEC 9240 (Bactec; BD Diagnostic Systems, Sparks, Md.), which was flagged negative within 24-48 hours. After 72 hours, only the first bottle was positive for *Staphylococcus epidermidis*.

Empirical antibiotic therapy was initiated with an intraperitoneal dose of cefazolin and ceftazidime (1 g) once a day. The catheter was removed and replaced due to the risk of peritonitis relapse. Afterwards, a peritoneal fluid sample was obtained and cultured on solid media and brain heart infusion (BHI) broth for aerobic etiology. The aerobic blood culture agar indicated slow-growing organisms (2-4 days) in the form of smooth white/cream colonies, with the average diameter of 2-3 millimeters (Figure 1A).

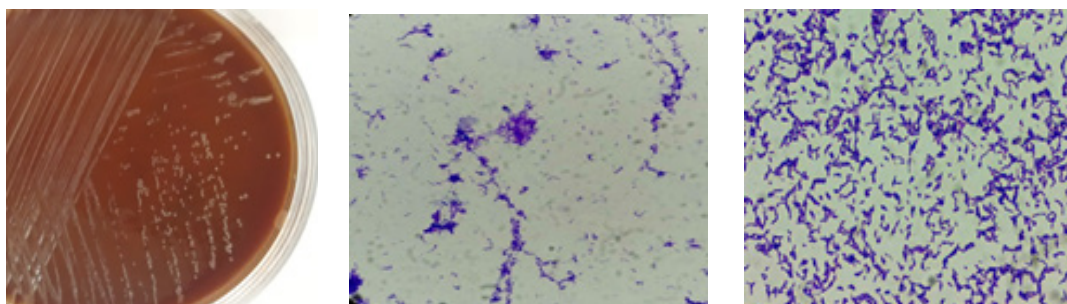


Figure 1. The yellowish non-hemolytic mucoid colonies of *Rothia dentocariosa* on blood agar after incubation for 24 hours. Isolate from case of this report (Left image; A). Microscopic image of the cultured isolates from the solid blood culture shows mixtures of gram-positive coccoid, diphtheroidal, filamentous rods (right images B & C) (Gram stain, $\times 1,000$).

Gram staining of colonies indicated a gram-positive coccoid to the rod-shaped bacterium, as well as the arrangement of diphtheroid to the branching rods (Figures 1-B and 1-C). After ensuring the purity and viability of the bacterium by the blood agar culture, the gram-positive isolate was assessed using the VITEK® 2 compact system (bioMérieux, Marcy l'Etoile, France), and a bacterial suspension was prepared with 0.45% sodium chloride solution and adjusted to the McFarland standard.

The gram-positive identification card contains 43 tests. In this study, the antibiotic susceptibility test was performed using the Kirby-Bauer disc-diffusion method on cation-adjusted Mueller-Hinton agar. The antibiotic discs (Rosco, Taastrup, Denmark) contained amikacin (30 µg), cefixime (30 µg), linezolid (30 µg), tetracycline (30 µg), vancomycin (30 µg), piperacillin-tazobactam (100/10 µg), ciprofloxacin (5 µg), clindamycin (2 µg), co-trimoxazole (25 µg), erythromycin (15 µg),

imipenem (10 µg), penicillin G (10 µg), gentamicin (10 µg), doxycycline (30 µg), ceftazidime (30 µg), and cephalothin (30 µg). In all the antibiotics, the inhibition zone was determined using species-related breakpoints for the other gram-positive aerobic cocci than *Staphylococcus* and *Enterococcus* (8,9). As a result, the patient became sensitive to all the tested antibiotics, with the exception of ciprofloxacin and cefixime.

After two days of antibiotic therapy, the patient had no fever, and the PD fluid was clear and colorless. In addition, the culture of the PD fluid was negative.

Discussion

In this study, we presented a case of peritonitis, in which *R. dentocariosa* was recovered from a peritoneal sample as the only organism. This bacterium is considered to be a normal flora of the oropharynx, while *Rothia* is an unusual cause of human diseases. The risk of the cardiac and ex-

tra-cardiac infections caused by *R. dentocariosa* has been reported to increase due to three main factors, including immunocompromised conditions, pre-existing cardiac disorders (e.g., mitral valve prolapse, bicuspid aortic valve, rheumatic mitral valvular disease, and prosthetic valve), and poor oral hygiene (6, 10, 11). However, our patient did not mention any dental procedures, paravalvular abscess or oral-jaw trauma, while PD peritonitis had presumably been caused by hematogenous spread from gingival or periodontal sources.

It is notable that no data were available regarding the hygienic dentition of the patient. In PD patients, oral hygiene may be one of the basic principles of preventing PD peritonitis. Therefore, it is speculated that our patient might have had an occult oral source of *R. dentocariosa*.

Conclusion

R. dentocariosa is found in the oral cavity and pharynx of humans, where it forms part of the normal microflora and is not commonly isolated from laboratory specimens (12). The large number of insignificant specimens from which *R. dentocariosa* is isolated by laboratories does not deduct the pathogenic potential of this organism (13). The main risk factors for the cardiac and extra-cardiac infections caused by *R. dentocariosa* include immunocompromised conditions, pre-existing cardiac disorders, and poor oral hygiene. In this study, we presented the case of a previously healthy PD patient with peritonitis. In PD patients, the observance of oral hygiene is one of the basic principles of PD peritonitis prevention. However, our patient did not mention any dental procedures, paravalvular abscess or oral-jaw trauma, and the PD peritonitis had presumably resulted from hematogenous spread from gingival or peri-

odontal sources. Therefore, it is speculated that our patient might have had an occult oral source of *R. dentocariosa*.

Acknowledgements

None.

Conflict of Interest

The authors declare no conflict of interest.

References

1. Piraino B, Bailie GR, Bernardini J, et al. ISPD guidelines/recommendations. *Perit Dial Int.* 2005;25:107-131.
2. Li PK, Szeto CC, Piraino B, et al. Peritoneal dialysis-related infections recommendations: 2010 update. *Perit Dial Int.* 2010;30:393-423.
3. Austin B. *Bergey's Manual of Systematics of Archaea and Bacteria.* Wiley :Hoboken, New Jersey ;2015.
4. von Graevenitz A, Pünter-Streit V, Riegel P, et al. Coryneform bacteria in throat cultures of healthy individuals. *J Clin Microbiol.* 1998;36:2087-2088.
5. Von Graevenitz A. *Rothia dentocariosa*: taxonomy and differential diagnosis. *Clin Microbiol Infect.* 2004;10:399-402.
6. Yang CY, Hsueh PR, Lu CY, et al. *Rothia dentocariosa* bacteremia in children: report of two cases and review of the literature. *J Formos Med Assoc.* 2007;106:S33-S38.
7. MacKinnon M, Amezaga M, MacKinnon J. A case of *Rothia dentocariosa* endophthalmitis. *Eur J Clin Microbiol Infect Dis.* 2001;20:756-757.
8. Kronvall G, Lannér-Sjöberg M, von Stedingk LV, et al. Whole cell protein and partial 16S rRNA gene sequence analysis suggest the existence of a second *Rothia* species. *Clin Microbiol Infect.* 1998;4:255-263.
9. Droz S, Zbinden R, Zbinden R. *Rothia dentocariosa*. Available at: <http://www.antimicrobe.org/b230.asp>.
10. Salamon SA, Prag J. Three cases of *Rothia dentocariosa* bacteraemia: frequency in Denmark and a review. *Scand J Infect Dis.* 2002;34:153-157.
11. Uchibori S, Tsuzukibashi O, Kobayashi T, Aida M. Localization of the genus *Rothia* in the oral cavity. *International Journal of Oral-Medical Sciences.* 2013;11:207-210.
12. Ferraz V, McCarthy K, Smith D, et al. *Rothia dentocariosa* endocarditis and aortic root abscess. *J Infect.* 1998;37:292-295.
13. Kong R, Mebazaa A, Heitz B, et al. Case of triple endocarditis caused by *Rothia dentocariosa* and results of a survey in France. *J Clin Microbiol.* 1998;36:309-310.