



C4d and C3d immunohistochemical evaluation on formalin-fixed paraffin-embedded tissue for the diagnosis of bullous pemphigoid: systematic review of the literatures

Mahsa Akbari Oryani (MD), Masomeh Safaei (MD)*, Farzane Farzam (MD), Hadi Razmara (MD), Navid Fathi (MD)

Department of Pathology, School of Medicine, Mashhad University of Medical Sciences, Mashhad, Iran.

ARTICLE INFO

Article type

Systematic review article

Article history

Received: 22 Nov 2015

Revised: 19 Feb 2016

Accepted: 6 Mar 2016

Keywords

Bullous pemphigoid

Complement Component 3d

Complement C4d

Immunohistochemistry

ABSTRACT

Introduction: Several methods are available for the diagnosis of autoimmune bullous disease. Since the immunohistochemistry of complement component is easy and more accessible compared to other methods, it is thought that this technique as an efficient method can replace other difficult, and time-consuming procedures. Therefore, in this study we aimed to systematically review the literatures in which the diagnostic value of complement component 3d (C3d) and C4d had been investigated in bullous pemphigoid.

Methods: A systematic search was conducted in the PubMed, Google scholar, and Scopus using following search method (((C3d OR C4d OR complement component 3d OR complement component 4d immunohistochemistry)) OR (C3d OR C4d marker OR complement component 3d OR complement component 4d marker)) AND (bullous pemphigoid OR cutaneous pemphigoid) to evaluate the diagnostic value of C3d and/or C4d for early and accurate detection of bullous pemphigoid on November 2015. Subsequently, the extracted data were described.

Result: Total of 28 documents were collected and reviewed based on the purpose of this study. Of the collected articles, 21 documents were excluded in several steps of article selection process and only 7 relevant articles were included for data assessment. The results showed that the deposits of C3d and/or C4d in skin biopsies were found in 125 of 134 patients, indicating that immunohistochemistry is a reliable technique for the diagnosis of inflammatory skin diseases.

Conclusion: The results of this review showed that C3d and/or C4d immunohistochemistry in skin biopsies is a reliable technique for the diagnosis of inflammatory skin diseases, particularly bullous pemphigoid.

Please cite this paper as:

Akbari Oryani M, Safaei M, Farzam F, Razmara H, Fathi N. C4d and C3d Immunohistochemical evaluation on formalin-fixed paraffin-embedded tissue for the diagnosis of bullous pemphigoid: systematic review of the literatures. *Rev Clin Med.* 2017;4(1):26-30.

Introduction

Autoimmune bullous disease (ABD) is a heterogeneous group of skin and mucous membrane disorder and may differ in clinical manifestation, histopathology, immunopathology, treatment and progression of the disease. ABDs are divided into two groups of sub-epidermal and intra-epider-

mal bullous diseases (1). The occurrence of ABD is mainly due to the immune response against desmosomes or basement membrane zone (2). Diagnosis of ABD is often based on clinical, histopathological, immunoblotting, and direct or indirect immunofluorescence findings. The most

*Corresponding author: Masomeh Safaei.

Department of Pathology, School of Medicine, Mashhad University of Medical Sciences, Mashhad, Iran.

E-mail: safaeim911@mums.ac.ir

Tel: 09151535700

This is an Open Access article distributed under the terms of the Creative Commons Attribution License (<http://creativecommons.org/licenses/by/3.0>), which permits unrestricted use, distribution, and reproduction in any medium, provided the original work is properly cited.

prevalent type of pemphigoid disease is probably bullous pemphigoid (3). Bullous pemphigoid, which is thought to be related to immune system disorders, is mainly characterized by large and tense blisters with mixed superficial inflammation that is rarely fatal. It is shown that the lesions of bullous pemphigoid usually start as an urticarial eruption, which may later develop into bullae (4). Population based studies have shown that yearly incidence rates of bullous pemphigoid is 6 to 14 cases per million in European regions (5,6). Bullous pemphigoid is predominantly manifested in elderly with age >65 years and with almost equal frequency in men and women (3,7). Findings show that the annual rate of mortality from bullous pemphigoid varies from 6% in the United States to 41% in France (8,9).

In sub-epidermal immunobullous diseases, immunofluorescence technique is often used as a diagnostic technique in which antibodies can bind to the tissue by direct immunofluorescence technique in the skin lesions, but direct immunofluorescence requires fresh frozen tissue and a well-equipped laboratory as well as skilled pathologists (4). Immunohistochemical evaluation of complement components is a diagnostic method in the evaluation of transplant kidney biopsies; moreover, complement components 3d (C3d) and C4d as humoral markers are indicative of transplant rejection. Although the contribution of mucous membranes is less common in bullous pemphigoid, but it has long been known that in bullous pemphigoid, autoantibodies are not only present in the circulatory system; rather they can deposit in the basement membrane of the skin (10). Deposition of immunoglobulin G (IgG) and C3 is demonstrated in bullous pemphigoid by direct immunofluorescence (DIF)(4). In addition, it has been found that immunohistochemical deposition of C3d and C4d can be a diagnostic tool in the diagnosis of inflammatory skin diseases (1). So far, little information is published about the use of immunohistochemistry on paraffin embedded tissues to demonstrate the deposition of complement component and immunoglobulins in the skin. Since the immunohistochemical technique is easier and more accessible, it is probable that this technique can replace other difficult, costly, and time-consuming procedure. In this study, we aimed to systematically review the literatures and review all available data in which the diagnostic value of C3d and C4d had been investigated in bullous pemphigoid.

Methods

Search methods

We conducted a comprehensive systematic search in the PubMed, Google scholar, and Scopus

using “complement component 3d and 4d” and “bullous pemphigoid” as search terms to evaluate the diagnostic value of C3d and C4d for early and accurate detection of bullous pemphigoid on November 2015. These key terms were searched in the title, abstract and keywords of articles in which the immunohistochemical deposition of C3d and C4d had been evaluated in the diagnosis of inflammatory skin diseases, particularly bullous pemphigoid. For this purpose, we used following search method (((C3d OR C4d OR complement component 3d OR complement component 4d immunohistochemistry)) OR (C3d OR C4d marker OR complement component 3d OR complement component 4d marker)) AND (bullous pemphigoid OR cutaneous pemphigoid) to find potentially eligible documents in the PubMed and Scopus. Then, by using a customized search, we limited the search results to only those articles published in English language. To minimize the probability of data loss, the reference lists of all included documents as well as Google scholar were searched for potentially relevant documents. All processes including literature search, and data analysis were performed by two authors independently.

Study selection

Due to the lack of enough data on the subject, no time limitation was defined during study selection. Hence, all documents relevant to the purpose of this study that had been published up to November 2015 were included in this literature review. However, the search was limited to those articles only published in English language. Documents with subject and language irrelevancy were left out in the first step of article selection process. Moreover, to minimize possible errors and misinterpretations, articles with almost all types of clinical design except abstracts and conference proceedings, editorials, review articles and meta-analysis were included. Similarly, literatures in which similar data of the same population had been reported or other duplicated documents were excluded. We also excluded articles with inaccessible full text from further evaluation. In addition, those studies that had been performed on animals were also excluded. Eligibility criteria for selected articles in this review included all articles reporting possible diagnostic value of C3d or C4d in inflammatory skin diseases, especially bullous pemphigoid.

Data extraction

General information including the name of first author, publication date, and the type of study design in addition to country and the total number of studied population in each study were extracted. Other accessible data, particularly demographic

data of studied population, methods of evaluation, and the major findings were collected from included documents based on the main purpose of this study. All related data were extracted and described based on the results of articles reporting the possible diagnostic role of C3d and C4d in inflammatory skin disease. According to the recommended protocol in PRISMA checklist 2009, all procedures including data processing, literature search, and study selection, as well as data synthesis were performed by two authors independently (11). To avoid any probable misinterpretation and errors during data analysis, any possible disagreements between the investigators were resolved in each step prior to further data processing.

Measured variables

Deposits of immunoglobulins (Ig) including IgG, IgM, IgA, IgD, IgE, Kappa and Lambda chains of antibodies, C3d and/or C4d, and albumin at the basement membrane of the skin in bullous pemphigoid, and also on the surface of epidermal keratinocytes in skin sections of the collected biopsies had been evaluated in some of included documents. Moreover, DIF test of frozen or fixed skin biopsy had also been used as reference standard to compare the results. Serological tests and endoscopy were also performed in some of included studies.

Results

Literature search results

Of total of 28 potentially relevant collected articles, 9 were in the PubMed, 8 in the Scopus and 5 in Google scholar. By reference list screening of the collected articles, 6 additional documents were also found and used for further evaluation. By reviewing the abstract of the collected articles, we crossed out 9 irrelevant articles in the first step due to irrelevancy. We further excluded other 4 articles due to duplication. By limiting the results to articles with English language, 2 articles were also excluded from further evaluation. In addition, we excluded one article that had been performed on animal and additional 3 papers including 2 articles with inaccessible full text and 1 review articles from additional assessment. Finally, full text of 9 articles in which the diagnostic value of C3d and/or C4d had been evaluated in patients with bullous pemphigoid were collected and used for further evaluation. After reviewing the content of selected documents, only 7 relevant articles that fully met the defined inclusion/exclusion criteria and contained data of 134 patients, published between 2008 and 2015, were included and used for data extraction and subsequent data processing. Figure 1 shows the step by step procedure of literature search and article selection.

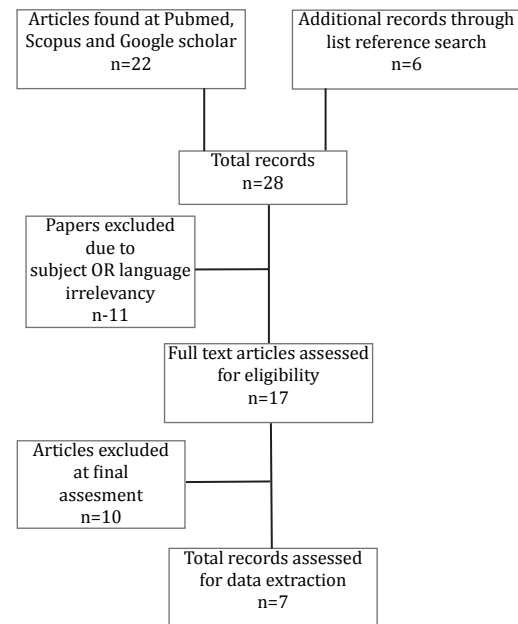


Figure 1. Flowchart of the literature search and strategy for the selection of relevant document.

General characteristics of the included articles

The total number of studied population enrolled in the selected articles in which the diagnostic value of C3d and/or C4d as inflammatory markers had been evaluated in patients with bullous pemphigoid was 134. The number of enrolled patients varied from 1 in a case report to 34 in a cross-sectional study among the included literatures. Both male and female patients had been participated in the selected documents. The sex ratio had not been reported in any of the included studies; hence, we could not report the data based on sex ratio. The most old and recent articles included in this survey had been published in 2008 and 2015, respectively. The selected articles used for data processing included 4 retrospective, 1 cross-sectional, 1 case report and 1 case-control study. The major characteristics of included literatures are demonstrated in Table 1 in their chronological order of published time.

Study findings

The results of this survey showed that immunohistochemistry of complement components particularly C3d and C4d as well as immunoglobulin assay can replace other expensive and time consuming methods. The results showed that the deposits of C3d and/or C4d in skin biopsies were found in 125 of 134 studied patients, indicating that immunohistochemistry compared to direct and indirect immunofluorescence is a reliable technique for the diagnosis of inflammatory autoimmune skin diseases. Number of positive tests for C3d and C4d, as well as main findings of each

Table 1. General information of the included literatures.

| No | Author Reference | Year | Country | Study design ® | Methods | Patients number |
|----|------------------|------|-------------|----------------|----------------------------------------------------------------------------------------------------------------|-----------------|
| 1 | Villani AP (12) | 2015 | France | RS | Skin biopsy, serological tests, C4d antibody | 29 |
| 2 | Velez AMA (13) | 2013 | USA | CSS | Immunoglobulin (IgG, IgM, IgA, IgD, IgE) assay, Kappa and Lambda chains, C3c, C1q, C3d, albumin and fibrinogen | 34 |
| 3 | Kwon EJ (14) | 2013 | USA | RS | Immunohistochemistry for anti-C4d, direct immunofluorescence | 12 |
| 4 | Zimmer V (15) | 2012 | Germany | CR | Endoscopy, immunohistochemistry, immunoglobulin assay | 1 |
| 5 | Pfaltz K (16) | 2010 | Switzerland | CCS | Immunohistochemical expression of C3d, immunoglobulin assay | 32 |
| 6 | Chandler W (17) | 2009 | USA | RS | C4d antibody | 9 |
| 7 | Magro CM (18) | 2008 | USA | RS | Expression of C3d and C4d | 17 |

® RS: Retrospective study, CSS: Cross-sectional study, CR: Case report, CCS: Case control study.

document is demonstrated in Table 2.

Discussion

Findings show that although complement components, particularly 4d (C4d) are rare cause of graft failure in organ transplantation, but immunostaining of these components is a useful technique for diagnosing antibody-mediated rejection (AMR). Moreover, it is shown that C4d

can be considered as hallmark of acute humoral rejection or as a marker of AMR (19,20). Recent studies have also demonstrated that C3d and C4d immunoassays can be considered as an important diagnostic adjunct for the accurate evaluation of collagen and cutaneous vascular disease, as well as autoimmune vesiculobullous disease (18).

Previously, the usefulness of erythrocyte-bound C4d and C4d-bearing reticulocytes as a sensitive

Table 2. Main findings of included literatures.

| No | Author Reference | Main findings * | Number of positive tests for C3d and C4d |
|----|------------------|--------------------------------------------------------------------------------------------------------------|------------------------------------------|
| 1 | Villani AP (12) | The accuracy of detection of C4d was higher than that of ELISA/ IIF(87% vs. 67%). | 25 (86.2%) C4d+ |
| 2 | Velez AMA (13) | Immunohistochemistry is as reliable as DIF and IIF for the diagnosis of autoimmune skin blistering diseases. | 98% C3d+ ® |
| 3 | Kwon EJ (14) | C4d immunohistochemistry may obviate the need of a repeat biopsy for DIF. | 10 (83.3%) |
| 4 | Zimmer V (15) | C4d or C3d immunostaining might be helpful in the assessment of esophageal autoimmune bullous diseases. | 1 (100%) C4d+ |
| 5 | Pfaltz K (16) | C3d immunohistochemistry is a valuable tool in the diagnosis of BP with a sensitivity of at least 97%. | 32 (97%) C3d+ |
| 6 | Chandler W (17) | C4d immunohistochemistry can be used for confirmation of basement membrane immunoreactant deposition in BP. | 7 (78%) C4d+ |
| 7 | Magro CM (18) | C3d and C4d assays are important diagnostic adjunct in the evaluation of autoimmune vesiculobullous disease. | 17 (100%) C3d+ Total: 125 |

*IIF: Indirect immunofluorescence, DIF: Direct immunofluorescence, BP: Bullous pemphigoid,

® The reported value is diagnostic correlation between immunohistochemistry and immunofluorescence for all cases of skin disease.

biomarker in the prediction of disease activity had been evaluated in patients with systemic lupus erythematosus (21). Platelet-bound C4d is also shown to be a reliable prognostic biomarker for the onset and severity of ischemic stroke and systemic lupus erythematosus as well as thrombosis (22-24). In addition to included documents, findings published in language other than English have also demonstrated that the expression of C3d and IgG in bullous pemphigoid tissue were 96% and 72.0%, respectively; therefore, it was deduced that the detection of C3d with immunohistochemical method may be helpful for the diagnosis of bullous pemphigoid (25). Similarly, it is demonstrated that the deposits of IgG antibodies and C3 is present in 95% and 100% of skin biopsies at the basement membrane zone (26). In this review, it was found that immunohistochemical assessment of C3d and/or C4d can be a tool with high specificity and selectivity for the accurate diagnosis of bullous pemphigoid, where this technique may not have suitable efficiency for the diagnosis of any other skin defect or lesion on the skin (14). But the specificity, selectivity and efficiency of this methods requires further investigations.

Major limitations of this review included the lack of literature regarding immunohistochemical assessment of paraffin-embedded tissue in skin samples, limited data on pathology and immunopathology of the disease, few numbers of patients in some studies and unreported demographic data of the studied populations. Therefore, due to risk of misinterpretation and possible errors, statistical comparisons of the data are avoided in this paper.

Conclusion

The results of this review showed that immunohistochemical assessment of C3d and/or C4d in skin biopsies is a reliable technique for the diagnosis of inflammatory skin diseases, particularly bullous pemphigoid. Therefore, C3d and/or C4d immunohistochemistry may be a helpful and accessible technique to replace other time consuming methods such as immunofluorescence.

Conflict of Interest

The authors declare no conflict of interest.

References

1. Yeh SW, Ahmed B, Sami N, et al. Blistering disorders: diagnosis and treatment. *Dermatol Ther*. 2003;16:214-223.
2. Mutasim DF. Therapy of autoimmune bullous diseases. *Ther Clin Risk Manag*. 2007;3:29-40.
3. Sagi L, Baum S, Agmon-Levin N, et al. Autoimmune bullous diseases the spectrum of infectious agent antibodies and review of the literature. *Autoimmun Rev*. 2011;10:527-535.
4. Bickle K, Roark TR, Hsu S. Autoimmune bullous dermatoses: a review. *Am Fam Physician*. 2002;65:1861-1870.
5. Cozzani E, Parodi A, Rebora A, et al. Bullous pemphigoid in Liguria: a 2-year survey. *J Eur Acad Dermatol Venereol*. 2001;15:317-319.
6. Gudi VS, White MI, Cruickshank N, et al. Annual incidence and mortality of bullous pemphigoid in the Grampian Region of North-east Scotland. *Br J Dermatol*. 2005;153:424-427.
7. Schmidt E, Zillikens D. Modern diagnosis of autoimmune blistering skin diseases. *Autoimmun Rev*. 2010;10:84-89.
8. Colbert RL, Allen DM, Eastwood D, et al. Mortality rate of bullous pemphigoid in a US medical center. *J Invest Dermatol*. 2004;122:1091-1095.
9. Roujeau JC, Lok C, Bastuji-Garin S, et al. High risk of death in elderly patients with extensive bullous pemphigoid. *Arch Dermatol*. 1998;134:465-469.
10. Damoiseaux J. Bullous skin diseases: classical types of autoimmune diseases. *Scientifica (Cairo)*. 2013;2013:457982.
11. Liberati A, Altman DG, Tetzlaff J, et al. The PRISMA statement for reporting systematic reviews and meta-analyses of studies that evaluate health care interventions: explanation and elaboration. *Ann Intern Med*. 2009;151:W65-94.
12. Villani AP, Chouvet B, Kanitakis J. Application of C4d Immunohistochemistry on Routinely Processed Tissue Sections for the Diagnosis of Autoimmune Bullous Dermatoses. *Am J Dermatopathol*. 2016;38:186-188.
13. Velez AMA, Googe Jr PB, Howard MS. Immunohistochemistry versus immunofluorescence in the diagnosis of autoimmune blistering diseases. *Our Dermatol Online*. 2013;4:585-595.
14. Kwon EJ, Ntiamoah P, Shulman KJ. The utility of C4d immunohistochemistry on formalin-fixed paraffin-embedded tissue in the distinction of polymorphic eruption of pregnancy from pemphigoid gestationis. *Am J Dermatopathol*. 2013;35:787-791.
15. Zimmer V, Muller CS, Juengling B, et al. Esophageal intramural pseudodiverticulosis in mucous membrane pemphigoid: potential diagnostic utility of C4d immunohistochemistry. *Dig Endosc*. 2012;24:487.
16. Pfaltz K, Mertz K, Rose C, et al. C3d immunohistochemistry on formalin-fixed tissue is a valuable tool in the diagnosis of bullous pemphigoid of the skin. *J Cutan Pathol*. 2010;37:654-658.
17. Chandler W, Zone J, Florell S. C4d immunohistochemical stain is a sensitive method to confirm immunoreactant deposition in formalin-fixed paraffin-embedded tissue in bullous pemphigoid. *J Cutan Pathol*. 2009;36:655-659.
18. Magro CM, Dyrsen ME. The use of C3d and C4d immunohistochemistry on formalin-fixed tissue as a diagnostic adjunct in the assessment of inflammatory skin disease. *J Am Acad Dermatol*. 2008;59:822-833.
19. Haga H, Egawa H, Fujimoto Y, et al. Acute humoral rejection and C4d immunostaining in ABO blood type-incompatible liver transplantation. *Liver Transpl*. 2006;12:457-464.
20. Aguilera I, Sousa JM, Gavilan F, et al. Complement component 4d immunostaining in liver allografts of patients with de novo immune hepatitis. *Liver Transpl*. 2011;17:779-788.
21. Yang DH, Chang DM, Lai JH, et al. Usefulness of erythrocyte-bound C4d as a biomarker to predict disease activity in patients with systemic lupus erythematosus. *Rheumatology (Oxford)*. 2009;48:1083-1087.
22. Kao AH, McBurney CA, Sattar A, et al. Relation of platelet C4d with all-cause mortality and ischemic stroke in patients with systemic lupus erythematosus. *Transl Stroke Res*. 2014;5:510-518.
23. Mehta N, Uchino K, Fakhran S, et al. Platelet C4d is associated with acute ischemic stroke and stroke severity. *Stroke*. 2008;39:3236-3241.
24. Navratil JS, Manzi S, Kao AH, et al. Platelet C4d is highly specific for systemic lupus erythematosus. *Arthritis Rheum*. 2006;54:670-674.
25. Kun GUO, GENG S-m. Detection of C3d expression in bullous pemphigoid. *Chinese J Dermatol*. 2012;45:364-365.
26. Khandpur S, Verma P. Bullous pemphigoid. *Indian J Dermatol Venereol Leprol*. 2011;77:450-455.